

Before You Send the Samples: Ingredients to Great Patient Care

Prof Dr Effat Omar

Anatomic Pathology Unit

Dept of Clinical Diagnostic Laboratories, UiTM



Contents of the talk



PATIENT CARE: THE ROLES WE
PLAY

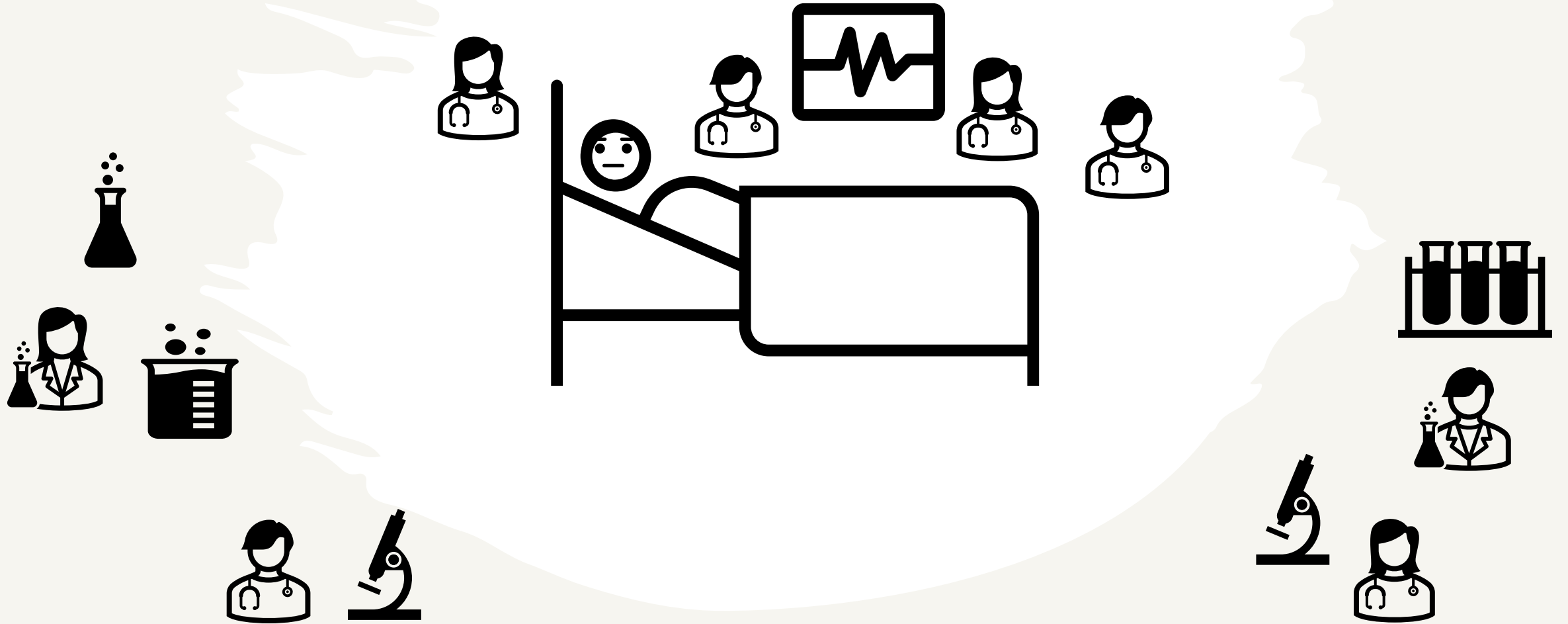

THE FLOW OF THE ANATOMIC
PATHOLOGY LABORATORY
PROCESSES



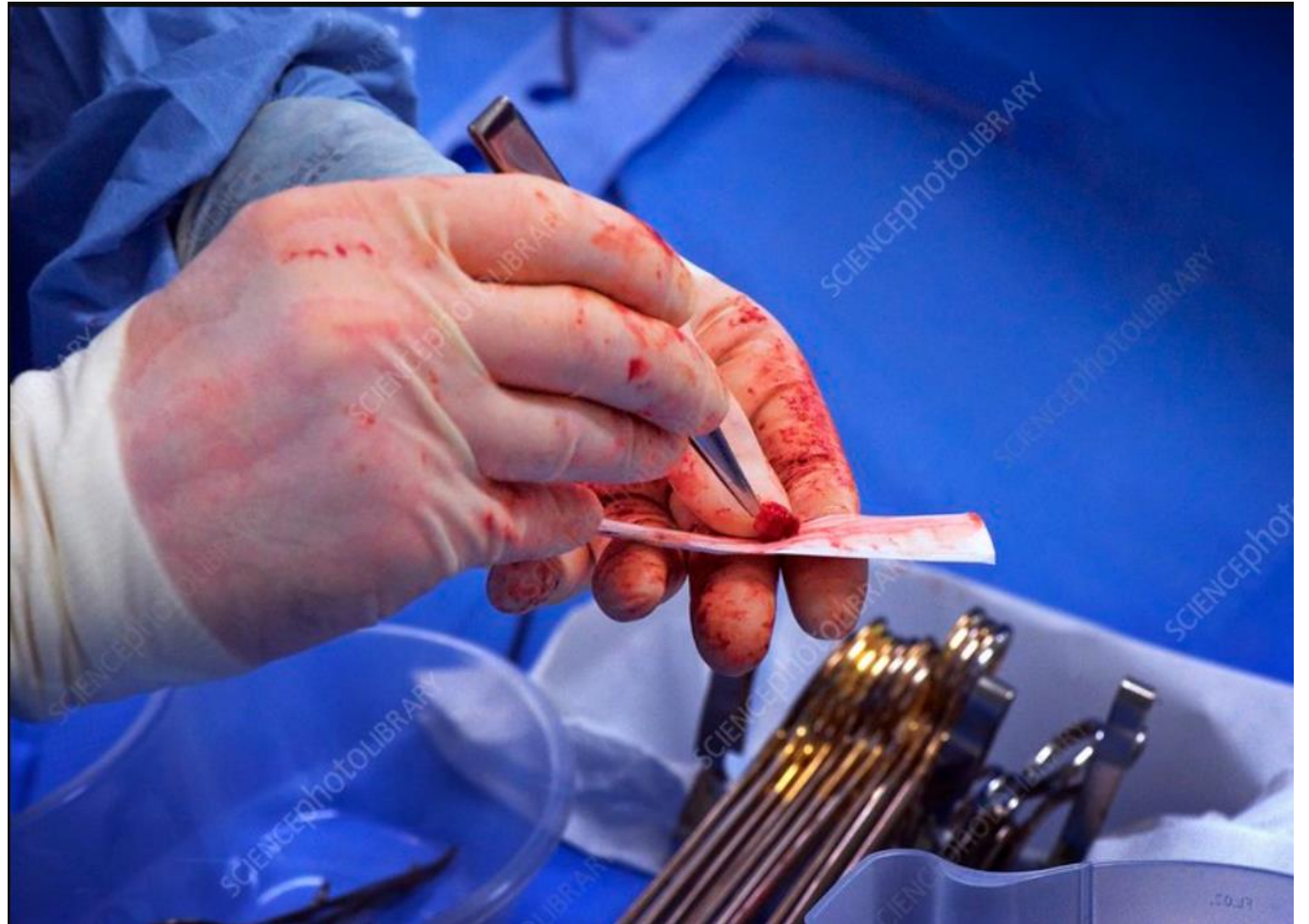
BEFORE YOU SEND THE
SAMPLES: TIPS FOR GREAT
PATIENT CARE

Our Roles in Patient Care

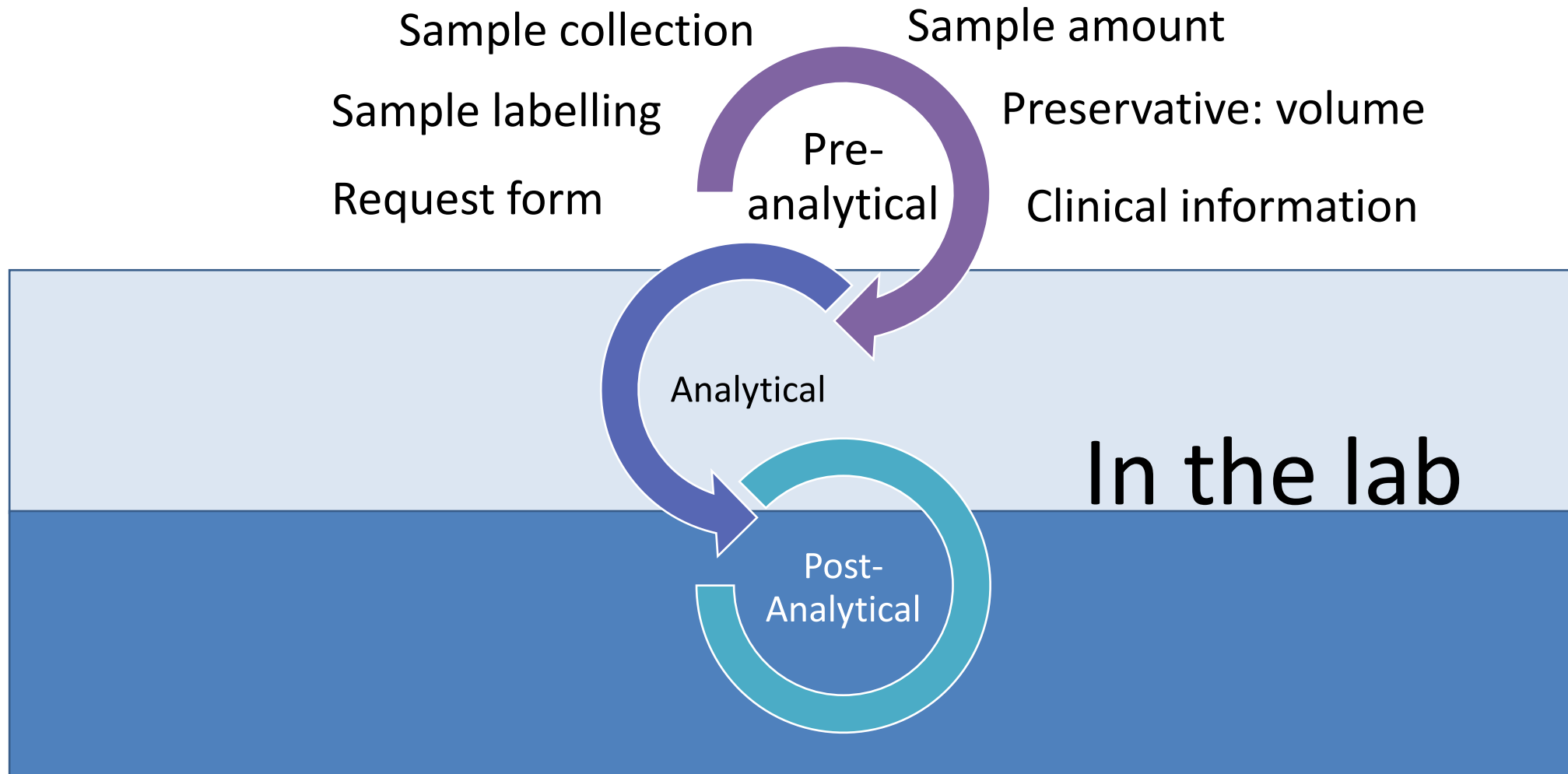


Tissue

- Precious
- Irreplicable
- Heterogeneous



Flow of an anatomic pathology laboratory

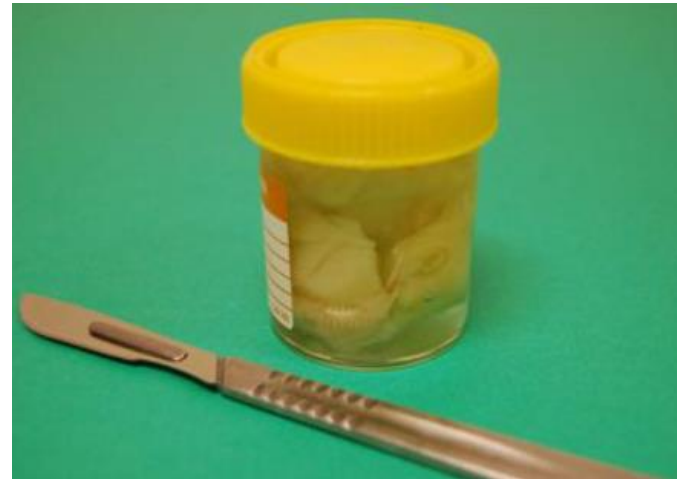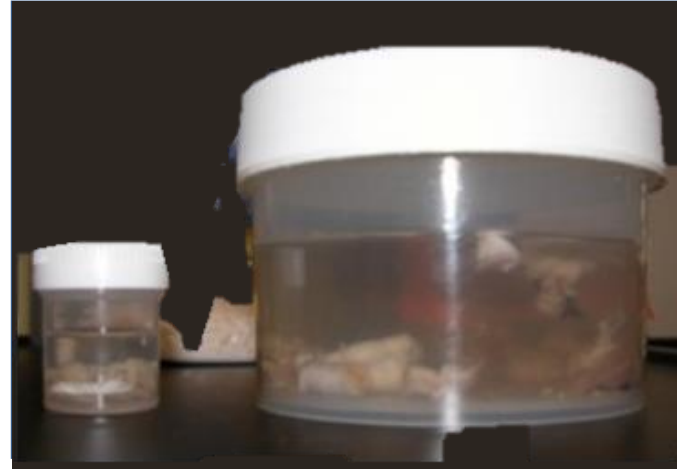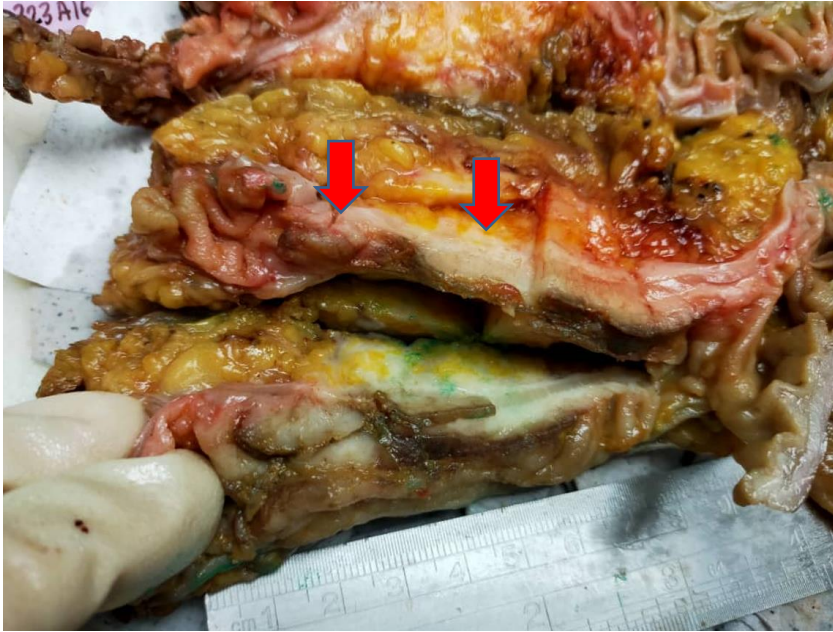


Specimen labelling

- Correct patient
- Identifiables (at least 2)
- Correct area label (including tags)
- Must be corrected before move further with the processes



Sampling and use of formalin



- Enough formalin to prevent decay of tissue
- Recommended: 1: 20 (for 16-hour fixation at room temperature)
(tissue : formalin, V/V)

Request form

- Patient identification

Clinical information ensures:

- Accuracy of interpretation
- Patient Safety
- Effectiveness

KEMENTERIAN KESIHATAN MALAYSIA
PERKHIDMATAN PATOLOGI
HOSPITAL SUNGAI BULOH

PER-PAT 301

2. No. Pendaftaran: SB 0007422

1. Nama
3. No. K
4. Jantina: Lelaki Perempuan

5. Umur: 38
6. Keturunan: MELAYU
7. Wad/Klinik:
8. Tarikh Masuk Wad: 25/9/2020
9. Pekerjaan:
10. Taraf Perkahwinan: 11. Bayar Percuma

12. No. Laporan Dahulu:
13. Butiran Pentane

14. Ringkasan Klinikal, Penerimaan Pembedahan dan Riwayat Keluarga:
SINAHIDA BINTI SAMSUBIN, 38 years old
allergy to Augmentin
History of treated as left buttock abscess, completed cloxacillin for 5 days.
Initially small then become bigger.
non tender
US left gluteal (29/9/2020)
- Left gluteal lesion may suggest as lipoma.
Suggest local excision as lesion has internal heterogeneity.
excisional biopsy done 25/9/2020
pre op diagnosis: left gluteal lipoma
post op diagnosis: left gluteal sebaceous cyst

15. Diagnosis: Left gluteal sebaceous cyst

16. Kategori Permohonan/Jenis Ujian:

Patologi Kimia	Klinikal	Hematologi	Histopatologi	Mikro-Immunologi
B. Sugar	Bld. Count	PPB	Specimen	Specimen
B. Urea	ESR	BM Asp.		Ujian
S. Elec	RFMP	Hb Analysis		
B. Gases	U. Sugar	Coagulation		
S. Billirubin	U. Alb.			
LFT	U. ME			
Se. Creatinine	Stool ME			

Lain-lain:

17. Pengamalan: Masa: PEGAWAI PERUBATAN
Dewan Bedah Am
Hospital Sungai Buloh
Tanjong

18. Nama D:
19. Tarikh:

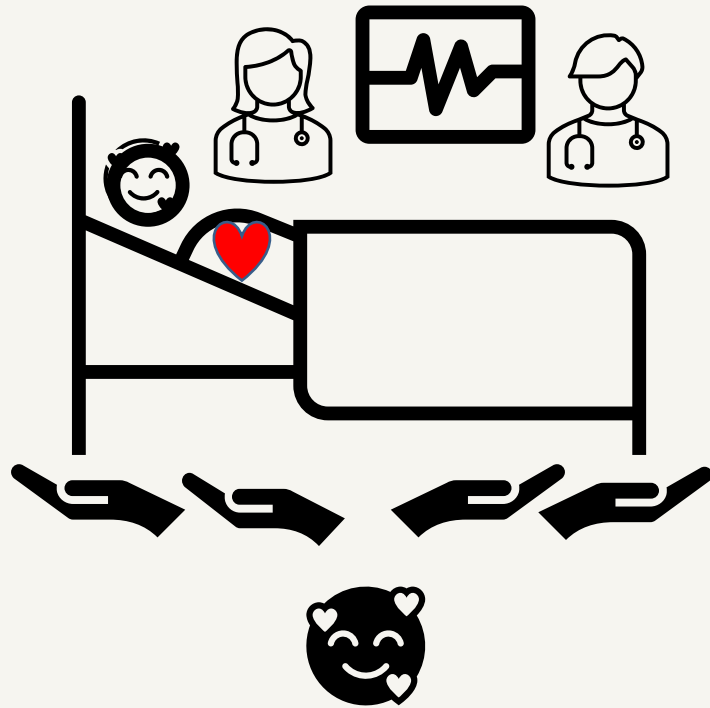
Tandatangan dan Cop Doktor

Guess what this is?

- Information:
 - A painting
 - by a famous artist
 - Painting by Van Gogh







Ingredient for great patient care:

Pre-analytical phase – within clients' control

Correct specimen: type/location

Use correct preservative in correct amount

Accurate labelling

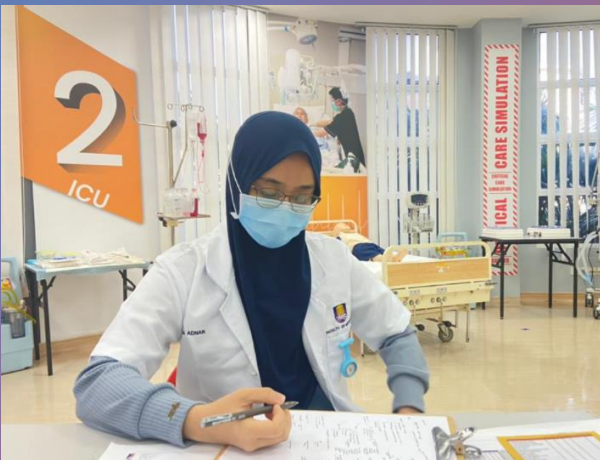Good/ relevant clinical information



Thank you for
your attention!

A little quiz:

1. Give TWO reasons why it is important to correctly label the specimen bottles.
2. Give THREE reasons why good clinical information should be provided with the specimen.



Answers

1. Why are tissue samples precious?

Answer: It is difficult to obtain and irreplaceable.

1. State TWO reasons why it is important to correctly label the specimen bottle.

Answer: patient safety and for accuracy of diagnosis

1. Give THREE reasons why good clinical information should be provided with the specimen.

Answer: patient safety, effectiveness of the process and for accuracy of diagnosis